



## Safety Assessment of *Lactobacillus paracasei* IBRC-M 11110 in Wistar Rats: A Subacute 28-Day Toxicity Study

Saba Bahrehvar 

(MSc) Department of Biology, Faculty of science, Urmia University, Urmia, Iran

Amir Abbas Barzegari 

(PhD) Department of Biology, Faculty of Basic Science, University of Maragheh, Maragheh, East Azerbaijan Province, Iran

Shiva Khezri 

(PhD) Department of Biology, Faculty of science, Urmia University, Urmia, Iran

Vahid Nejati 

(PhD) Department of Biology, Faculty of science, Urmia University, Urmia, Iran

**Corresponding author:** Amir Abbas Barzegari

**Tel:** +984137278001

**Email:** Barzegaridoctora@gmail.com

**Address:** Department of Biology, Faculty of Basic Science, University of Maragheh, Maragheh, East Azerbaijan Province, Iran

**Received:** 2021/01/19

**Revised:** 2021/05/03

**Accepted:** 2021/05/05



© The author(s)

DOI: 10.29252/mlj.15.5.19

### ABSTRACT

**Background and objectives:** Safety is a key criterion for assessment of probiotics. The objective of this study was to evaluate safety of a new Iranian *Lactobacillus paracasei* IBRC-M 11110 strain as a candidate probiotic.

**Methods:** Eighteen male and 18 female Wistar rats were divided into two experimental and a control group. The experimental groups received the bacterium at two doses of  $6 \times 10^8$  CFU/day and  $6 \times 10^9$  CFU/day for 28 days through oral gavage. The control groups received normal saline. On day 29, blood, serum and tissue samples were taken for analysis.

**Results:** Administration of the bacterium did not affect the general health and body weight of the rats during the study period. No significant change was observed in the blood parameters of rats in the experimental groups except for a significant decrease in mean corpuscular volume and mean corpuscular hemoglobin of male rats. Serum analysis showed a significant increase in the alanine transaminase and a significant decrease in aspartate transaminase in the experimental groups of male and female rats, respectively. In both male and female rats, a significant decrease in urea and a significant increase in creatinine were observed in the experimental groups. However, the above parameters were all within the normal range. Histopathological analysis of liver and kidney tissues also showed no abnormality.

**Conclusion:** The results confirm that *L. paracasei* IBRC-M 11110 was safe in the subacute toxicity test in Wistar rats.

**Keywords:** [Lactobacillus paracasei](#), [Toxicity tests](#), [Rats](#), [Safety](#).

## INTRODUCTION

Some microorganisms including various bacteria and yeasts species are known as probiotics (1, 2). According to the World Health Organization (WHO), probiotics are live microorganisms with beneficial health effects if used in sufficient amounts (3). Probiotics can contribute to food digestion, production of vitamins and antibiotics and improvement of immune functions (4). Moreover, studies on the use of probiotics for the prevention or treatment of diseases have reported promising results (5-11). Considering these beneficial effects, the use of probiotics is on the rise. Nowadays, many pharmaceuticals as well as functional foods contain probiotics (12). Therefore, researchers are interested in introducing new strains of probiotics as the beneficial effects are strain-dependent. One of the most important features of a probiotic is its safety. In this regard, the WHO has developed guidelines for the evaluation of probiotics safety (13).

*Lactobacillus* is one of the most important genera of probiotics. Lactobacilli belong to the lactic acid bacteria (LAB) group. These gram-positive and catalase-negative cocci can tolerate low pH (14). Various species of lactobacilli are generally recognized as safe (GRAS). However, the consumption of some LAB species may lead to diseases such as bacteremia, endocarditis and abscesses (15-18). *Lactobacillus paracasei* IBRC-M 11110 is a lactic acid-producing Iranian strain. The bacterium has been isolated from dairy products and is considered as a candidate probiotic. To our knowledge, there is no information about the safety of this *Lactobacillus* strain in the literature. Therefore, the purpose of the present study was to evaluate the safety of *L. paracasei* IBRC-M 11110 in Wistar rats.

## MATERIALS AND METHODS

*L. paracasei* IBRC-M 11110 was purchased from the Iranian Genetic Resource Center (Tehran, Iran). The bacterial strain was cultured in MRS broth (QUELAB LABORATORIES INC, Canada) at 37 °C for 48 hours. The bacterial culture was then centrifuged at 5000 × g for 10 minutes. The precipitate was washed three times with physiological serum. To make bacterial suspensions, normal saline was used as diluent. Then, bacterial suspensions were

prepared at densities of  $6 \times 10^8$  and  $6 \times 10^9$  colony-forming unit (CFU). The suspensions were freshly prepared every day, just before being fed to the animals through a gavage needle.

In this research, 18 male and 18 female Wistar rats weighing between 220-250 g were enrolled. The rats were obtained from the animal house of Urmia University (Iran) and transported to the University of Maragheh. At first, the animals were subjected to a 7-day adaptation period. Animal maintenance and experiments were conducted in standard conditions: temperature of between 22 - 25 °C, free access to water and standard rodents' pellets and a circadian rhythm with 12-12 light/dark cycles. The ethics committee of the University of Maragheh approved the experimental protocols (UM-2019-number 24). The animals were divided randomly to six groups each containing six animals.

This study was conducted according to the Organization for Economic Cooperation and Development (OECD) guidelines (test no. 407) that has been adopted in October 2008. According to this guideline, animals receive one dose of the substance of interest, daily, for 28 days. Overall, four experimental groups (two from each gender) received  $6 \times 10^8$  and  $6 \times 10^9$  CFU of bacteria by oral gavage and a basal diet (BD) for 28 consecutive days. In the same period, the control groups received only the basal diet and 100 µl of sterile saline via oral gavage. In the subacute oral toxicity test, general observations were carried out to find any changes in the appearance or behavior of the rats. The body weight of the rats was measured on days 7, 14, 21 and 28. Moreover, the level of food and water consumption was monitored during the 28-day period.

At the end of the experiment, after 12 to 14 hours of fasting, the animals were anesthetized with ketamine (100 mg/kg) and xylazine (20 mg/kg). Then, blood, serum and tissue samples were taken for hematological, biochemical and histopathological evaluations, respectively. The blood samples were analyzed using an automated analyzer (Selectra XL, Vital scientific, Netherlands) to determine the following parameters: hemoglobin (Hb), white blood cell count (WBC), red blood cell count (RBC), mean corpuscular hemoglobin concentration (MCHC), mean corpuscular volume (MCV), mean corpuscular hemoglobin

(MCH), hematocrit (HCT), platelets blood count (PLT) and lymphocytes count. Blood samples were allowed to be coagulated using clot activator-containing tubes. After coagulation, the samples were centrifuged at 3000 rpm for 20 minutes. Then, plasma was separated to analyze concentration of alanine amino transaminase (ALT), aspartate amino transaminase (AST), alkaline phosphatase (ALP), urea and creatinine (19). At the end of the experiment, the liver and kidney tissues of the rats were extracted and fixed in 10% formalin solution. Other steps of tissue processing including alcohol dehydration, clearing, wax infiltration and embedding were conducted. Then, the paraffin blocks were cut into 10- $\mu\text{m}$  slices. The tissue sections were mounted onto slides and stained with hematoxylin and eosin. Finally, a histologist blind to the research evaluated the stained tissues for any pathological changes. Data were presented as mean  $\pm$  standard deviation. Statistical analysis of data was performed in SPSS software using one-way analysis of variance (ANOVA) and post hoc Tukey's test. A p-value of less than 0.05 was considered statistically significant.

## RESULTS

No mortality occurred during the 28-day period.

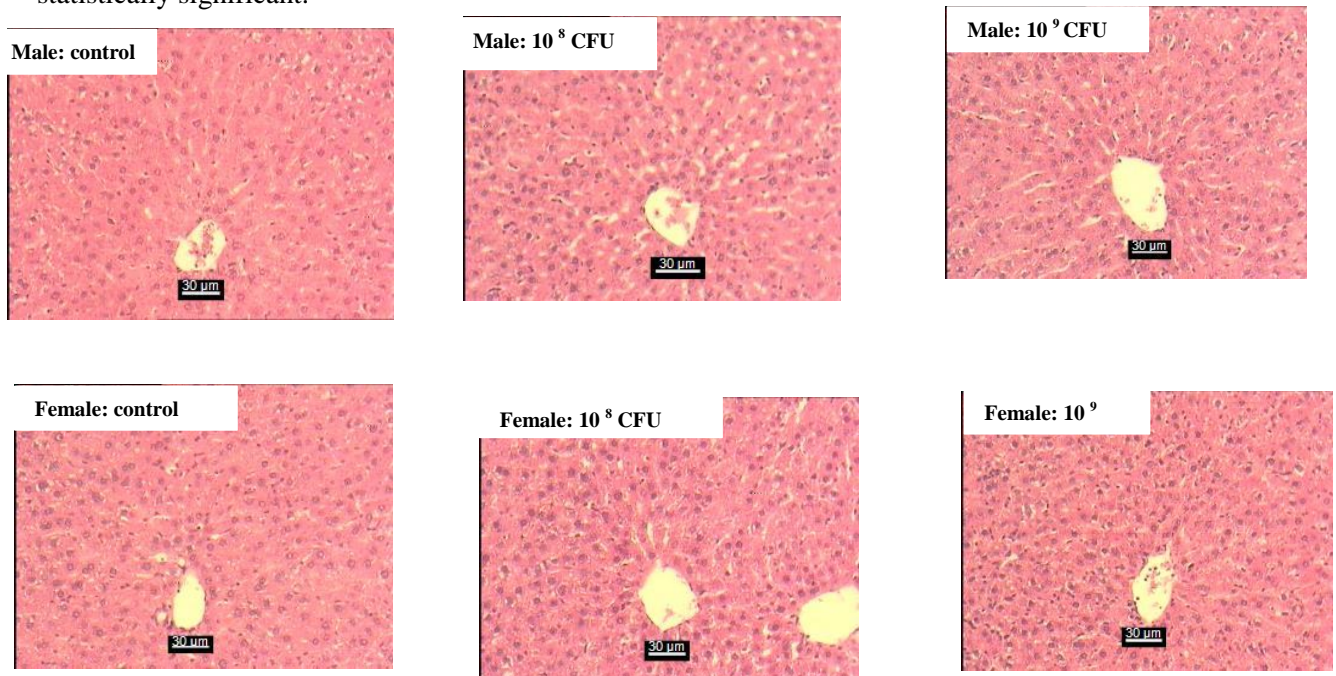
In addition, no change in the skin, fur, eyes, mucous membranes and secretions was observed. On the behavioral aspects, no change associated with the treatments was observed.

Overall, the administration of different doses of bacteria to the rats induced no considerable morbidity or mortality in the animals. Daily consumption of food and water did not change significantly in the study groups. Moreover, no significant difference was observed in the mean weight of rats on days 7, 14, 21 and 28.

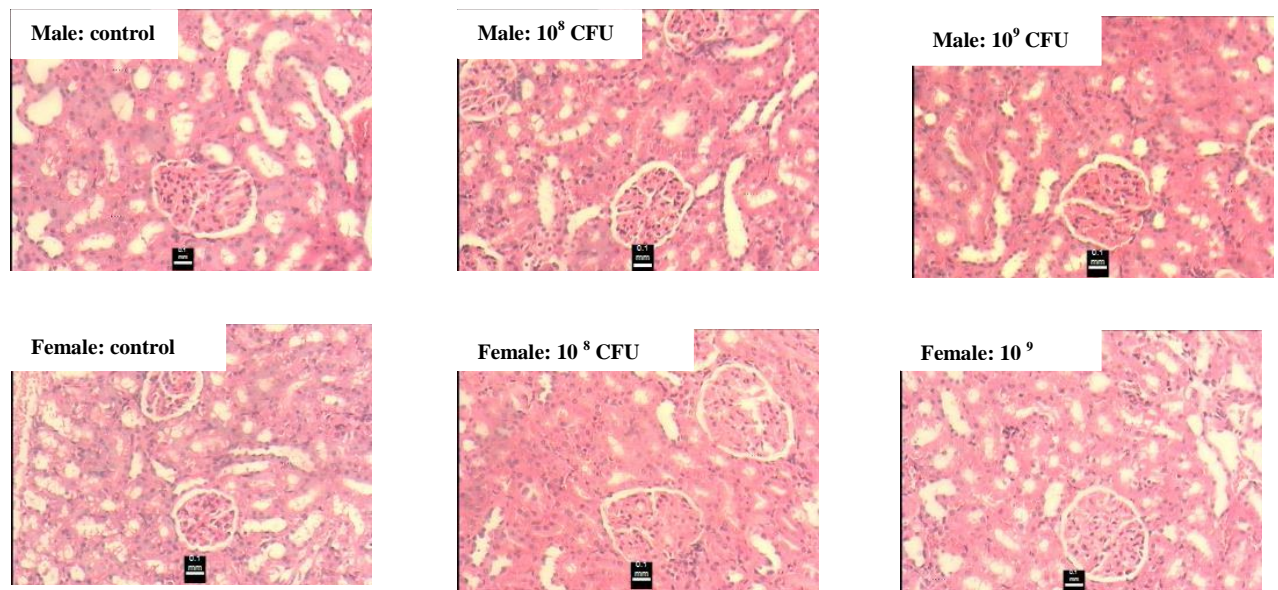
[Table 1](#) shows the effects of different doses of *L. paracasei* IBRC-M 11110 on the blood parameters.

No statistically significant difference in the blood parameters was observed between the female rats in the experimental groups and the control group. Male rats in the experimental groups had significantly lower MCV and MCH levels than those in the control group.

Other blood parameters did not differ significantly between male rats in the experimental and control groups.



**Figure 1-** Effect of *L. paracasei* IBRC-M 11110 consumption on structural features of liver tissues following hematoxylin and eosin staining (images were taken under 400X magnification). Both male and female had normal hepatic tissue. and Scale bar = 30  $\mu\text{m}$ . Hepatocytes (H), Sinusoids (S), Central vein (CV), Proximal (P), Glomerulus (G), Distal (D), Urinary space (US).



**Figure 2-** Effect of *L. paracasei* IBRC-M 11110 on structural features of kidney tissue. The kidney tissues of male and female rats in the experimental groups had normal structure. Scale bar = 0.1 mm. Glomerulus (G), Proximal tubule (P), Distal tubule (D), Urinary sinus (US).

The effects of different doses of *L. paracasei* (IBRC-M 11110) on the biochemical parameters of rats are shown in [table 2](#). In male rats, there was no significant difference in the concentrations of AST and ALP between the control and the experimental groups. However, male rats receiving  $6 \times 10^9$  CFU of *L. paracasei* had significantly higher level of ALT compared to the respective control group. In female rats, AST decreased significantly in the animals receiving the lower dose of bacteria. In both sexes, urea decreased significantly and creatinine level increased significantly in the experimental groups.

After 28 days of bacteria administration, no histological abnormality in the liver and kidney tissues was observed in the experimental groups compared to the respective control groups. Liver lobules had normal structure ([Figure 1](#)). Similarly, the renal tissue showed no anomaly and the glomeruli as well as distal and proximal tubules had normal appearance ([Figure 2](#)).

## DISCUSSION

The objective of the present research was to evaluate the safety of oral administration of *L. Paracasei* IBRC-M 11110 in rats. The 28-day oral administration of the bacterium had no significant toxic effect on both male and female Wistar rats. During the 28-day study

period, the rats had a healthy appearance and normal behavior. An indicator of general health status of animals in toxicity studies is the change in body weight. A significant decrease in the body weight of animals may be due to some adverse toxic effects including loss of appetite, diarrhea and dehydration. Therefore, one of the reasons for the lack of the toxicity of the bacterium in the rats was the normal weight change of the experimental animals during the study period ([20](#)).

Toxic doses of xenobiotics can alter blood parameters ([21](#)). Therefore, these blood biomarkers are good indices for assessment of physiological status in animals. Changes in hematological parameters may be an indication of inflammation or infection in the body. On the other hand, the increase in ALT, AST, ALP, urea and creatinine may indicate a problem in the liver or kidney ([21](#)). In the present study, no significant difference was observed in the hematological parameters of the animals fed with *L. paracasei* IBRC-M 11110 except for a decrease in the amount of MCV and MCH in male rats. MCV is a biomarker showing the size of erythrocytes. Low and high MCV indicate the presence of microcytic and macrocytic erythrocytes in blood, respectively. MCH represents the mean amount of hemoglobin in a single erythrocyte. Both low MCV and MCH may indicate microcytic anemia. However, in our study, the

level of these parameters was in the normal range, indicating that the bacterium had no adverse effects on the volume or hemoglobin content of erythrocytes. In a similar study, it was found that administration of different doses of *Lactobacillus fermentum* PL9005 for

28 days had no major effect on hematological parameters (22).

In another study, administration of *Lactobacillus casei* reduced MCV in the experimental groups compared to the control group (23).

Table 1- Effect of *L. paracasei* IBRC-11110 on blood parameters\* P < 0.05 compared with control group

Group	WBC ( $\times 10^3/\mu\text{L}$ )	Lym (%)	RBC ( $\times 10^6/\mu\text{L}$ )	HGB (g/dL)	HCT (%)	MCV (fL)	MCH (pg)	MCHC (g/dL)	PLT ( $\times 10^3/\mu\text{L}$ )
Male Control	7.7 $\pm$ 3.1	74.3 $\pm$ 5.6	8 $\pm$ 0.15	13 $\pm$ 0.39	42 $\pm$ 0.71	54 $\pm$ 0.45	18.8 $\pm$ 0.18	32.40 $\pm$ 0.18	850 $\pm$ 86
Female	4.89 $\pm$ 0.8	69 $\pm$ 3.7	6.8 $\pm$ 0.2	12.8 $\pm$ 0.15	39.1 $\pm$ 0.74	53.8 $\pm$ 1	17.6 $\pm$ 0.22	32.4 $\pm$ 0.5	856 $\pm$ 41.4
Male $1 \times 10^8$ CFU	8.32 $\pm$ 0.9	70.4 $\pm$ 7.5	8.21 $\pm$ 0.26	13.2 $\pm$ 0.48	41.5 $\pm$ 1.48	50.4 $\pm$ 0.82	16 $\pm$ 0.38	31.8 $\pm$ 0.31	868 $\pm$ 48.8
Female	3.87 $\pm$ 1.38	65.6 $\pm$ 5.8	7.17 $\pm$ 0.17	12.62 $\pm$ 0.17	38.4 $\pm$ 0.2	53.7 $\pm$ 1.36	17.6 $\pm$ 0.31	32.8 $\pm$ 0.39	737.7 $\pm$ 97.7
Male $1 \times 10^9$ CFU	8.16 $\pm$ 1.3	78.1 $\pm$ 1.1	8.2 $\pm$ 0.1	13.3 $\pm$ 0.24	41.1 $\pm$ 0.67	50.9 $\pm$ 0.59	16.5 $\pm$ 0.22	32.3 $\pm$ 0.22	758 $\pm$ 40.4
Female	5.7 $\pm$ 0.9	76.2 $\pm$ 1.1	7 $\pm$ 0.15	12.18 $\pm$ 0.4	37.3 $\pm$ 0.83	52.9 $\pm$ 0.62	17.34 $\pm$ 0.29	32.74 $\pm$ 0.4	791.8 $\pm$ 59.9

Table 2- Effect of *L. paracasei* IBRC-11110 on biochemical parameters

Group	ALP (U/L)	ALT (U/L)	AST (U/L)	Urea (mg/dl)	Creatinine (mg/dl)
Male Control	867 $\pm$ 100	55 $\pm$ 5	128 $\pm$ 12.1	39 $\pm$ 2	0.74 $\pm$ 0.2
Female	6 $\pm$ 62.619	80.6 $\pm$ 16.40	$\pm$ 15.8.150.8	47.1 $\pm$ 1.9	0.76 $\pm$ 0.16
Male $1 \times 10^8$ CFU	692.4 $\pm$ 337.8	67 $\pm$ 10.8	109.4 $\pm$ 10.5	29.8 $\pm$ 2.2	0.8 $\pm$ 0.4
Female	462 $\pm$ 123.8	68 $\pm$ 8.8	84.2 $\pm$ 51	32.5 $\pm$ 2	0.87 $\pm$ 0.5
Male $1 \times 10^9$ CFU	996.5 $\pm$ 165.4	78.6 $\pm$ 15.7	121.6 $\pm$ 15.1	28.3 $\pm$ 3.9	0.84 $\pm$ 0.3
Female	566.8 $\pm$ 146.3	68.8 $\pm$ 10.9	104 $\pm$ 5	27.6 $\pm$ 1.8	0.89 $\pm$ 0.8

These discrepancies in the results may be related to the effects of gender or the difference in the type of strains used in the experiments. Similar to a previous study (24), the administration of the bacterium did not significantly stimulate the immune system.

We measured levels of AST, ALT and ALP to evaluate effect of the bacterium on liver function. In case of liver damage, the serum level of these enzymes increases (25). Unlike ALT, which is mainly found in the liver, AST is found in many other tissues, including the heart, kidneys and brain. Hence, the elevation of AST in the serum is a less specific indicator for liver damage. ALP is present in the liver, bones, placenta, intestines and stomach. Increased ALP activity indicates a dysfunction of the biliary system. ALP may also increase in all types of liver diseases (26). In the present study, the level of ALT and AST increased and decreased significantly in the experimental groups of male and female rats, respectively. However, the findings do not necessarily indicate liver damage since the level of these enzymes was still in the normal range. Previous research has shown that the use of some lactobacilli in food had different effects on liver enzymes. In a study on combined administration of several lactobacilli (*L. rhamnosus* + *L. rhamnosus* + *L. plantarum*), ALT levels reduced compared to the control group (27). In another study, a combination of two probiotics (*L. casei* and *L. paracasei*) increased the level of ALT compared to the control group (28).

In clinical practice guidelines, determination of serum urea and creatinine concentrations is a good indicator of renal function. Urea is an excretory substance that is filtered by kidney glomeruli and excreted through urine (29). Similarly, creatinine is a waste product that is produced through the breakdown of creatinine phosphate in muscle cells (30). In our study, urea concentration decreased significantly after 28 days of *L. paracasei* IBRC-M 11110 administration. This is in line with findings of a study on the effects of daily probiotics consumption on urea of chronic kidney patients (31). On the other hand, the high level of creatinine in this study may indicate kidney damage. However, creatinine was in the reference range, so the potential risk of kidney damage induced by the bacterium is minimal. Moreover, analysis of the liver and kidney tissue sections showed no abnormal

pathological change. The findings support the results of serum analysis for lack of organ-related toxicity following the *L. paracasei* consumption.

## CONCLUSION

In the present subacute toxicity study, administration of *L. paracasei* IBRC-M 11110 at doses of  $1 \times 10^8$  and  $1 \times 10^9$  CFU/day was safe and did not induce toxic effects on Wistar rats. However, further research is needed to confirm safety of this bacterium as a probiotic.

## ACKNOWLEDGEMENTS

The authors would like to thank the staff of University of Maragheh and Urmia University.

## CONFLICT OF INTEREST

The authors declare that there is no conflict of interest.

## REFERENCES

- Sanders ME, Akkermans LM, Haller D, Hammerman C, Heimbach J, Hörmannspenger G, et al. *Safety assessment of probiotics for human use*. Gut Microbes. 2010 ;1(3):164-85. [DOI:10.4161/gmic.1.3.12127] [PubMed] [Google Scholar]
- Son HK, Chang HC, Lee JJ. *Acute and Subacute Oral Toxicity Evaluation of Crude Antifungal Compounds Produced by Lactobacillus plantarum HD1 in Rats*. Prev Nutr Food Sci. 2015 ;20(3):190-7. [DOI:10.3746/pnf.2015.20.3.190] [PubMed] [Google Scholar]
- Tsai CC, Chen MH, Liu TH, Chau CG, Chang LT, Tsai CC, et al. *Evaluation of the toxicity of Lactobacillus acidophilus LAP5 in a 28- Day feeding study in Wistar rats*. Journal of food safety. 2004;24(4):268-80. [View at Publisher] [DOI:10.1111/j.1745-4565.2004.00542.x] [Google Scholar]
- Dodoo CC, Wang J, Basit AW, Stapleton P, Gaisford S. *Targeted delivery of probiotics to enhance gastrointestinal stability and intestinal colonisation*. Int J Pharm. 2017 15;530(1-2):224-229. [View at Publisher] [DOI:10.1016/j.ijpharm.2017.07.068] [PubMed] [Google Scholar]
- Honeycutt TC, El Khashab M, Wardrop RM 3rd, McNeal-Trice K, Honeycutt AL, Christy CG, et al. *Probiotic administration and the incidence of nosocomial infection in pediatric intensive care: a randomized placebo-controlled trial*. Pediatr Crit Care Med. 2007 ;8(5):452-8; 464. [DOI:10.1097/01.PCC.0000282176.41134.E6] [PubMed] [Google Scholar]
- Barzegari AA, Hashemzaei M, Alihemmati A-R, Soltani S, Naseri B. *Effects of Lactobacillus rhamnosus (ATCC 7469) ointment on second-degree burn wound in Wistar rat*. Journal of Basic Research in Medical Sciences. 2018;5(1):1-9. [View at Publisher] [DOI:10.29252/jbrms.5.1.1] [Google Scholar]

7. Barzegari AA, Hashemzadei M, Majdani R, Alihemmati A-R. *Effects of topical treatment of second-degree burn wounds with Lactobacillus acidophilus on the wound healing process in male rats*. *Pharmaceutical and Biomedical Research*. 2017;3(3):23-30. [DOI:10.29252/pbr.3.3.23] [Google Scholar]
8. Vitellio P, Celano G, Bonfrate L, Gobbetti M, Portincasa P, De Angelis M. *Effects of Bifidobacterium longum and Lactobacillus rhamnosus on Gut Microbiota in Patients with Lactose Intolerance and Persisting Functional Gastrointestinal Symptoms: A Randomised, Double-Blind, Cross-Over Study*. *Nutrients*. 2019;11(4):886. [DOI:10.3390/nu11040886] [PubMed] [Google Scholar]
9. Zagato E, Mileti E, Massimiliano L, Fasano F, Budelli A, Penna G, et al. *Lactobacillus paracasei CBA L74 metabolic products and fermented milk for infant formula have anti-inflammatory activity on dendritic cells in vitro and protective effects against colitis and an enteric pathogen in vivo*. *PLoS One*. 2014; 10;9(2):e87615. [DOI:10.1371/journal.pone.0087615] [PubMed] [Google Scholar]
10. Choi SS, Kim Y, Han KS, You S, Oh S, Kim SH. *Effects of Lactobacillus strains on cancer cell proliferation and oxidative stress in vitro*. *Lett Appl Microbiol*. 2006; 42(5):452-8. [View at Publisher] [DOI:10.1111/j.1472-765X.2006.01913.x] [PubMed] [Google Scholar]
11. Gamallat Y, Meyiah A, Kuugbee ED, Hago AM, Chiwala G, Awadasseid A, et al. *Lactobacillus rhamnosus induced epithelial cell apoptosis, ameliorates inflammation and prevents colon cancer development in an animal model*. *Biomed Pharmacother*. 2016; 83:536-541. [View at Publisher] [DOI:10.1016/j.biopha.2016.07.001] [PubMed] [Google Scholar]
12. Abatenh E, Gizaw B, Tsegay Z. *Health benefits of probiotics*. *J Bacteriol Infec Dis* 2018; 2 (1): 8. 2018;27. [Google Scholar]
13. Indian Council of Medical Research Task Force; Co-ordinating Unit ICMR; Co-ordinating Unit DBT. *ICMR-DBT guidelines for evaluation of probiotics in food*. *Indian J Med Res*. 2011; 134(1):22-5. [PubMed] [Google Scholar]
14. Ramiah K, Ten Doeschate K, Smith R, Dicks LM. *Safety Assessment of Lactobacillus plantarum 423 and Enterococcus mundtii ST4SA Determined in Trials with Wistar Rats*. *Probiotics Antimicrob Proteins*. 2009; 1(1):15-23. [View at Publisher] [DOI:10.1007/s12602-009-9010-2] [PubMed] [Google Scholar]
15. Salminen MK, Tynkynen S, Rautelin H, Saxelin M, Vaara M, Ruutu P, et al. *Lactobacillus bacteremia during a rapid increase in probiotic use of Lactobacillus rhamnosus GG in Finland*. *Clin Infect Dis*. 2002; 35(10):1155-60. [View at Publisher] [DOI:10.1086/342912] [PubMed] [Google Scholar]
16. Mackay AD, Taylor MB, Kibbler CC, Hamilton-Miller JM. *Lactobacillus endocarditis caused by a probiotic organism*. *Clin Microbiol Infect*. 1999; 5(5):290-292. [View at Publisher] [DOI:10.1111/j.1469-0691.1999.tb00144.x] [PubMed] [Google Scholar]
17. Husni RN, Gordon SM, Washington JA, Longworth DL. *Lactobacillus bacteremia and endocarditis: review of 45 cases*. *Clin Infect Dis*. 1997; 25(5):1048-55. [View at Publisher] [DOI:10.1086/516109] [PubMed] [Google Scholar]
18. Naqvi SSB, Nagendra V, Hofmeyr A. *Probiotic related Lactobacillus rhamnosus endocarditis in a patient with liver cirrhosis*. *IDCases*. 2018; 18.13 [View at Publisher] [DOI:10.1016/j.idcr.2018.e00439] [PubMed] [Google Scholar]
19. YATZIDIS H. *Measurement of transaminases in serum*. *Nature*. 1960; 2;186:79-80. [DOI:10.1038/186079a0] [PubMed] [Google Scholar]
20. Stevenson R, Woods Jr WA. *Condition indices for conservation: new uses for evolving tools*. *Integrative and comparative biology*. 2006; 46(6):1169-90. [View at Publisher] [DOI:10.1093/icb/icl052] [PubMed] [Google Scholar]
21. Pletterino C, Argentino-Storino A. *Clinical chemistry and haematology historical data in control Sprague-Dawley rats from pre-clinical toxicity studies*. *Experimental and Toxicologic Pathology*. 2006; 57(3):213-9. [View at Publisher] [DOI:10.1016/j.etp.2005.10.002] [PubMed] [Google Scholar]
22. PARK J-H, Lee Y, Moon E, SEOK S-H, BAEK M-W, LEE H-Y, et al. *Safety assessment of Lactobacillus fermentum PL9005, a potential probiotic lactic acid bacterium, in mice*. *Journal of microbiology and biotechnology*. 2005; 15(3):603-8. [Google Scholar]
23. Haghayegh Zavareh BS, Madani M, Ghandehari F. *The Effect of the Lactobacillus casei on Hematological Parameters in Rat Infected with Candida albicans*. *Qom Univ Med Sci J*. 2019; 13(6):38-46. [View at Publisher] [DOI:10.29252/qums.13.6.38] [Google Scholar]
24. Panigrahi A, Kiron V, Puangkaew J, Kobayashi T, Satoh S, Sugita H. *The viability of probiotic bacteria as a factor influencing the immune response in rainbow trout Oncorhynchus mykiss*. *Aquaculture*. 2005; 243(1-4):241-54. [View at Publisher] [DOI:10.1016/j.aquaculture.2004.09.032] [Google Scholar]
25. Subbarao V, Gupta M. *Changes in serum transaminases due to hepatotoxicity and the role of an indigenous hepatotonic Liv. 52*. *Probe*. 1978; 17(2):175-8. [Google Scholar]

26. Giannini EG, Testa R, Savarino V. *Liver enzyme alteration: a guide for clinicians*. *Cmaj*. 2005;172(3):367-79. [[View at Publisher](#)] [[DOI:10.1503/cmaj.1040752](#)] [[PubMed](#)] [[Google Scholar](#)]
27. Adawi D, Ahrné S, Molin G. *Effects of different probiotic strains of Lactobacillus and Bifidobacterium on bacterial translocation and liver injury in an acute liver injury model*. *International journal of food microbiology*. 2001;70(3):213-20. [[View at Publisher](#)] [[DOI:10.1016/S0168-1605\(01\)00550-5](#)] [[PubMed](#)] [[Google Scholar](#)]
28. Seyedi B, Heidary R, Tukmechi A. *Dietary effect of L. casei and L. paracasei as probiotic bacteria with Raftilose as prebiotic on the growth and liver enzymes in rat*. *Razi Journal of Medical Sciences*. 2013;20(107):1-9. [[View at Publisher](#)] [[Google Scholar](#)]
29. Corbett JV. *Laboratory tests and diagnostic procedures: Englewood Cliffs, NJ: Prentice Hall Health*; 2000. [[View at Publisher](#)]
30. Sharma P, Tomar SK, Goswami P, Sangwan V, Singh R. *Antibiotic resistance among commercially available probiotics*. *Food Research International*. 2014;57:176-95. [[View at Publisher](#)] [[DOI:10.1016/j.foodres.2014.01.025](#)] [[Google Scholar](#)]
31. Ranganathan N, Ranganathan P, Friedman EA, Joseph A, Delano B, Goldfarb DS, et al. *Pilot study of probiotic dietary supplementation for promoting healthy kidney function in patients with chronic kidney disease*. *Advances in therapy*. 2010;27(9):634-47. [[View at Publisher](#)] [[DOI:10.1007/s12325-010-0059-9](#)] [[PubMed](#)] [[Google Scholar](#)]

How to Cite:

Bahrevar S, Barzegari AB, Khezri SH, Nejati V [Safety Assessment of *Lactobacillus paracasei* IBRC-M 11110 in Wistar Rats: A Subacute 28-Day Toxicity Study]. *mljgoums*. 2021; 15(5): 19-26 DOI: 10.29252/mlj.15.5.19